Flowchart Cat

LABOKLIN
LABORATORY FOR CLINICAL DIAGNOSTICS

Pruritus

↕

Medical history

↕

Clinical examination → **Ectoparasites: NO**

↓

Ectoparasites: YES

Notoedres

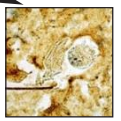
Notoedres

- Massive pruritus
- Owner and/or other cats also affected
- Scaly, crusty margins of pinnae

↓

Superficial skin scrapings, diagnostic treatment

↓

Pruritus resolved

Cheyletiella

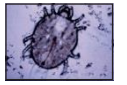
Cheyletiella

- White scales on the cat´s back
- Other animals/humans also affected

↓

Tape stripes, diagnostic treatment

↓

Pruritus resolved

Demodex PLUS secondary bacterial infection

Demodex

- Alopecia, scales, crusts, comedones

↓

(Deep) skin scrapings, Demodex PCR, cytology (+ pyoderma = pruritus)

↓

Demodex and antibacterial therapy

↓

Pruritus resolved

Other ectoparasites

Poultry mite

- *Otodectes cynotis*
- Harvest mite/*Neotrombicula autumnalis*
- Poultry mite/*Dermanyssus gallinae*
- Fleas /*Ctenocephalides felis*

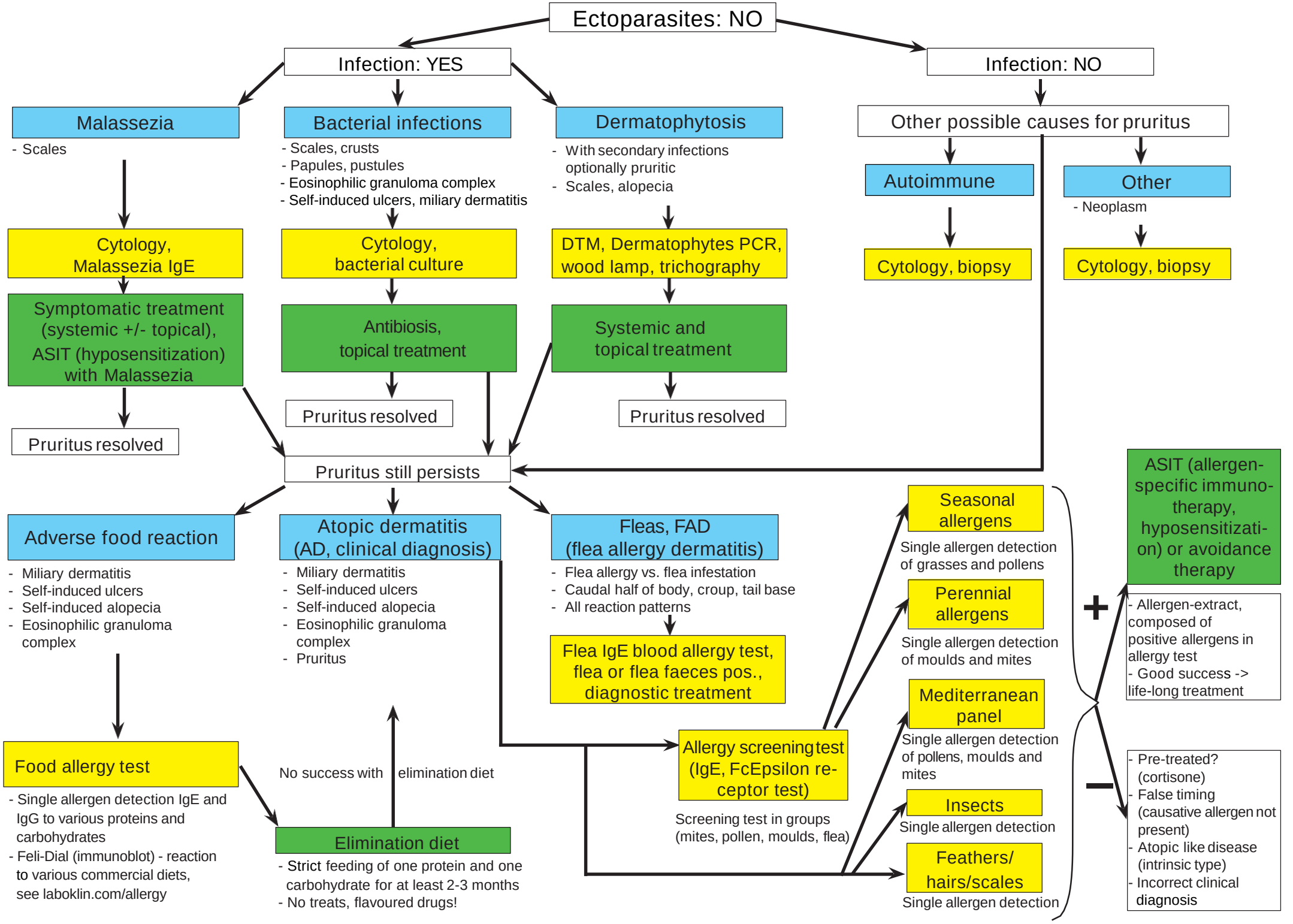
Ectoparasites: NO
Infection: YES
Infection: NO
Malassezia
- Scales
Bacterial infections
- Scales, crusts
- Papules, pustules
- Eosinophilic granuloma complex
- Self-induced ulcers, miliary dermatitis
Dermatophytosis
- With secondary infections optionally pruritic
- Scales, alopecia
Other possible causes for pruritus
Autoimmune
Other
- Neoplasm
Cytology, Malassezia IgE
Cytology, bacterial culture
DTM, Dermatophytes PCR, wood lamp, trichography
Cytology, biopsy
Cytology, biopsy
Symptomatic treatment (systemic +/- topical), ASIT (hyposensitization) with Malassezia
Antibiosis, topical treatment
Systemic and topical treatment
Pruritus resolved
Pruritus resolved
Pruritus resolved
Pruritus still persists
Adverse food reaction
- Miliary dermatitis
- Self-induced ulcers
- Self-induced alopecia
- Eosinophilic granuloma complex
Atopic dermatitis (AD, clinical diagnosis)
- Miliary dermatitis
- Self-induced ulcers
- Self-induced alopecia
- Eosinophilic granuloma complex
- Pruritus
Fleas, FAD (flea allergy dermatitis)
- Flea allergy vs. flea infestation
- Caudal half of body, croup, tail base
- All reaction patterns
Flea IgE blood allergy test, flea or flea faeces pos., diagnostic treatment
Food allergy test
- Single allergen detection IgE and IgG to various proteins and carbohydrates
- Feli-Dial (immunoblot) - reaction to various commercial diets, see laboklin.com/allergy
No success with
elimination diet
Elimination diet
- Strict feeding of one protein and one carbohydrate for at least 2-3 months
- No treats, flavoured drugs!
Allergy screening test (IgE, FcEpsilon receptor test)
Screening test in groups (mites, pollen, moulds, flea)
Seasonal allergens
Single allergen detection of grasses and pollens
Perennial allergens
Single allergen detection of moulds and mites
Mediterranean panel
Single allergen detection of pollens, moulds and mites
Insects
Single allergen detection
Feathers/ hairs/scales
Single allergen detection
+
ASIT (allergen-specific immuno-therapy, hyposensitizati-on) or avoidance therapy
- Allergen-extract, composed of positive allergens in allergy test
- Good success -> life-long treatment
−
- Pre-treated? (cortisone)
- False timing (causative allergen not present)
- Atopic like disease (intrinsic type)
- Incorrect clinical diagnosis